

23 THE BREAST AND ITS DISORDERS IN CHILDHOOD AND ADOLESCENCE*

The female breast undergoes remarkable growth during late childhood and early adolescence. In addition, it is subject to a variety of disorders that are of concern to gynecologists, pediatricians, and primary care physicians who see premenarchial and adolescent patients. Certain of these conditions, notably those of a developmental nature, those related to genetic defects, and those associated with endocrine disturbances, are relatively common. Benign tumors of the breast are discovered infrequently in patients less than 16 years of age, and malignant tumors of the breast are rare in young girls. The various disorders, including tumors, that the physician might discover in children and adolescents may be classified into eight major categories, as shown in Table 23-1.

DEVELOPMENT

The first signs of breast development appear at about the time the localized fat deposits begin to create a visible feminine body contour. The primary change in the breast is enlargement and projection of the nipple above the level of the areola (Fig. 23-1). Coincident with, or shortly after, the enlargement of the nipple, the breast becomes slightly elevated and the areola a trifle larger and a little darker in color, i.e., the "breast bud" stage of development (Fig. 23-2). It is at this stage that a small, flat, button-like disk of firm tissue occasionally

appears beneath the nipple of one or both breasts. Such nodules often cause mothers much concern because they fear these "lumps" are tumors. They are actually the start of the breast parenchyma, and nothing, other than observation and giving reassurance to the mother, should be done about them.

The next step in development after the bud stage is one in which the breast becomes a cone-shaped mass (Fig. 23-3) that protrudes from the chest wall. The areola continues to enlarge and become darker. After this, in some but not all girls, the areola forms a mound, or caplike plaque, on top of the rounded or conical mass. According to Tanner (1962), this plaquelike mound is present in 50 per cent of girls, slight in 25 per cent, and absent in 25 per cent. One of us (J. W. H.) has found it in not over 25 per cent of the adolescents he has examined and questions whether it should be considered a stage in breast growth, although it is included in the breast development stages patterned after that formulated by Reynolds and Wines (1948) and used by Tanner (Table 23-2).

According to Roche et al. (1971), the areo-

*The authors wish to thank the Medical Department of Harper & Row Publishers, Inc., for permission to paraphrase or incorporate in this chapter portions of the paper, together with certain of its illustrations, by Capraro, V. J., and Dewhurst, C. J.: Breast Disorders in Childhood and Adolescence, which appeared in *Clinical Obstetrics and Gynecology*, 18:25, 1975.

Table 23-1. CLINICAL CLASSIFICATION OF BREAST DISORDERS IN CHILDHOOD AND ADOLESCENCE

Modifications of Physiologic Responses
Neonatal hypertrophy
Asymmetry
Painful engorgement
Micromastia
Macromastia (virginal hypertrophy)
Galactorrhea
Atrophy
Nondevelopment
Virilizing congenital adrenal cortical hyperplasia
Gonadal dysgenesis
Pituitary hypogonadism
Amastia
Surgical excision of immature gland
Radiation castration
Bilateral ovariectomy
Radiation therapy to thoracic wall
Hermaphroditism
Premature Development
Premature thelarche
Constitutional isosexual precocity
Pseudoprecocious puberty
Congenital Anomalies
Amastia
Athelia
Polymastia
Polythelia
Lesions of Nipple and Areola
Inflammations
Trauma
Tumors
Benign
Malignant

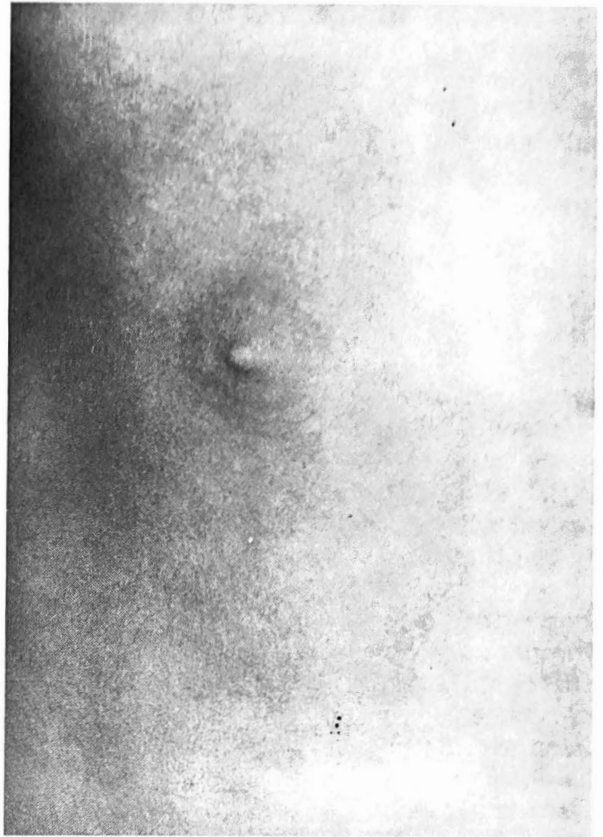


Figure 23-1. The first stage in breast development is enlargement and projection of the nipple above the flat chest wall.

la does not appear in some children until after they are 10 years of age. These authors note also that areolar size is not related to a child's chronological age, her pubic hair growth, age at peak height velocity, thickness of body fat, age at the menarche, or body size. They suggest that genetic factors are important in determining areolar size.

There is considerable variation in mammary gland growth at the menarche, but by the time many girls have had their first period, their breasts have almost attained their adult form. They have become either protuberant cone-shaped or round, full-fleshed, firm masses that stand out from the chest wall. The areola is dark and well pigmented; the nipples project above the surface of the glands and are erectile. The specialized sebaceous glands of Montgomery are beginning to appear about the margin of the areola. The firm, turgid enlargement of the breast at this time is due to a proliferation of the ductal elements within the fat gland mass. The acinar components of the breast do not take form until later.

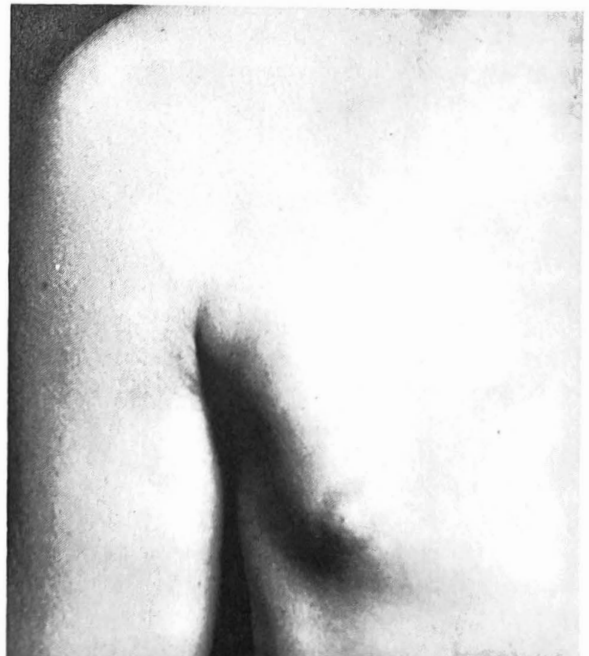


Figure 23-2. The second stage in breast development is elevation of the breast, continued enlargement of the nipple, and darkening of the areola.

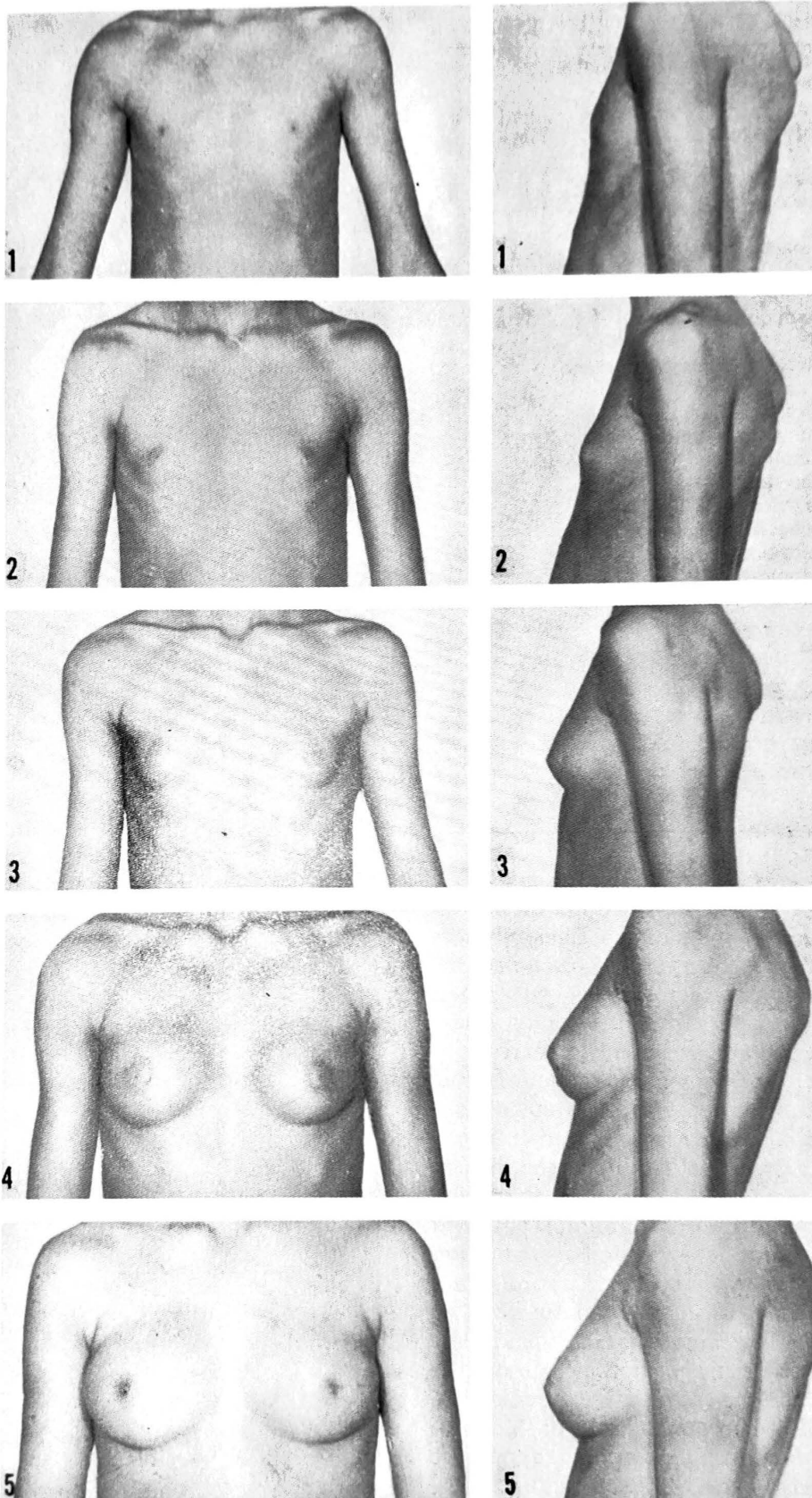


Figure 23-3. Standards for breast development ratings. Descriptions of each stage are given in Table 23-2. (From Tanner, J.M.: *Growth at Adolescence*, 2nd ed. Oxford, Blackwell Scientific Publications, 1962.)

Table 23-2. STAGES IN BREAST DEVELOPMENT

Stage 1.	Elevation only of papilla (nipple) No palpable parenchyma No enlargement of areola
Stage 2.	Elevation of papilla; breast forms small mound Enlargement and darkening of areola Button-like subpapillary parenchyma (not constant) So-called bud stage
Stage 3.	Further elevation and enlargement of areola and parenchyma No separation of contours between areola and rest of breast Further darkening of areola
Stage 4.	Plaquelike elevation of areola above gland mass (see text)
Stage 5.	Round, spherical or globular gland Erectile nipple Pigmentation and enlargement of areola Montgomery's glands evident

EXAMINATION

Examination of a newborn infant in the nursery includes inspection and palpation of the baby's breasts. Rarely, one or both nipples are absent (athelia). Normally, breast tissue can be palpated beneath the nipple because in late fetal life the mammary glands respond to the elevated levels of maternal hormones present at that time. Failure to palpate breast tissue raises the question of whether or not it is absent (amastia). A few infants are born with breast engorgement accompanied by some discharge, but this condition disappears in a few days.

During childhood a little girl's breasts are inspected and palpated at the time of a periodic well-child examination. The examiner notes the presence of congenital anomalies, tumefactions, and signs of precocious development and also records the appearance of the breast buds and assures the child's mother that they are the beginning of growth of normal breast tissue, not tumors.

Examination of the breasts is an essential part of a general and gynecologic examination of an adolescent girl even when she does not complain of symptoms related to her breasts. The need for periodic examination and the importance of self-examination

are explained to her, and she is shown how to examine her own breasts. It is important that such instructions be accompanied by an explanation, geared to the patient's ability to understand, of the unlikelihood that girls of her age would develop cancer, that any lump she may discover in her breasts would probably be benign, and that self-examination will become increasingly important as she grows older.

The examination is performed in a good light and preferably during the week after a menstrual period, when there is minimal hormonal stimulation. The normally somewhat granular consistency of breast tissue and the small, innocuous, slightly larger masses in the breasts of some patients during the premenstrual period should not be confused with pathologic tumefactions.

The examination begins with inspection, which is performed with the patient, disrobed to the waist, sitting on the examination table, first with her arms akimbo and then with them raised over her head. Anomalies, discharge from the nipples, skin lesions, discolorations, inflammation, variations in size and contour, and retraction or dimpling of the skin are identified at this time.

Palpation is carried out with the patient first lying supine on the table and then sitting up and leaning forward. The tips of the examiner's fingers move in a circular fashion, beginning at the outer margin of the gland and moving inward in ever smaller circles toward the nipple; this assures that all parts of the breast are palpated for tumors. The outer quadrants of each gland are repalpated after the patient crosses her arm on that side over to the opposite shoulder. Palpation is repeated, using the palmar surface of the hand, first of each breast and then of both breasts simultaneously. The axillae are palpated when the patient is sitting, when she is supine, and when she is bending forward. The supraclavicular areas are searched for enlarged lymph nodes when the patient is both sitting and supine. Performed in this manner, palpation of the breasts will reveal most masses larger than 1 centimeter in diameter.

The patient is asked if she has had any discharge from either breast, and each nipple is gently pressed to express any fluid in the lacteal ducts. Discharge from the nipples is discussed hereinafter.

Ancillary tests sometimes used in the

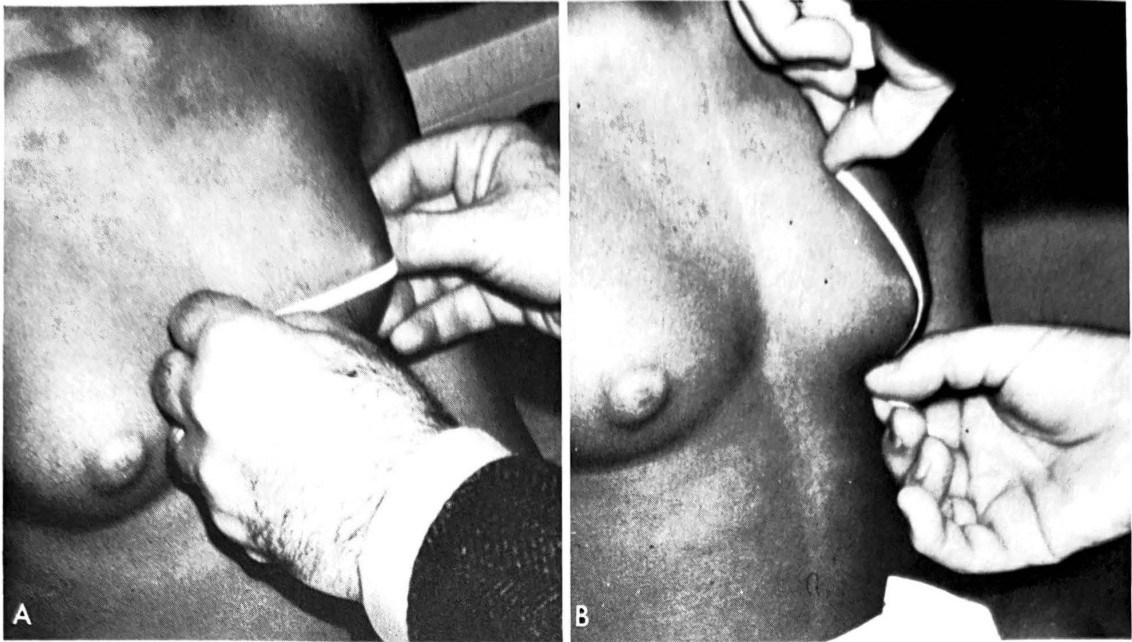

Figure 23-4. A, The examiner, using a centimeter tape, first measures the breast from 3 to 9 o'clock. B, The second measurement is made from 12 to 6 o'clock.

diagnosis of breast lesions include transillumination, thermography, mammography, and the alcohol sponge test described by Leis (1975). Biopsy is indicated in selected cases.

At times it is desirable to know whether or not a girl's breasts are developing normally by observing their increasing size over a period of several months. In some cases it is also advantageous to determine whether or not differences in the sizes of the two breasts are of clinical significance. In order to more accurately measure breast

size, one of us (V.J.C.) devised a technique for breast measurement. This technique may be used in following up the development of normal breasts as well as of breasts showing asymmetric development. With a centimeter tape measure, the breast is measured from 3 o'clock to 9 o'clock (Fig. 23-4, A) and from 12 o'clock to 6 o'clock (Fig. 23-4, B). These two measurements are multiplied, yielding a figure called the breast unit. Table 23-3 shows the typical spread of breast units in a normal adolescent.

Table 23-3. BREAST MEASUREMENTS IN A NORMAL PATIENT

Age	Right Breast		Left Breast	
	Measurements	"Breast Units"	Measurements	"Breast Units"
11 years	4.5 × 5.5 cm.	24.75	4.5 × 3 cm.	13.5
11 1/2 years	13 × 10 cm.	130	13 × 9 cm.	117
11 3/4 years	15 × 11 cm.	165	15 × 10.5 cm.	157.5
12 years	15 × 12 cm.	180	15.5 × 11 cm.	170.5
13 years	15 × 11 cm.	165	15 × 11 cm.	165
14 years	19 × 13 cm.	247	18 × 14 cm.	252
15 years	21 × 17 cm.	357	17 × 20 cm.	340
16 years	22 × 18 cm.	396	18 × 21 cm.	378

The "breast units" show an increase in size of both breasts with repeated examinations as the child grows. Note that in this normal patient, the "breast units" for each breast at any given time are not exactly equal but relatively similar. The right breast tends throughout the years to be slightly larger than the left breast. This is completely within normal limits and corresponds to the usual slight difference in the size of the hands, eyes, ears, etc. (From Capraro, V., and Dewhurst, C.: Breast disorders in childhood and adolescence. Clin. Obstet. Gynecol., 18:25, 1975.)

MODIFICATIONS OF PHYSIOLOGIC RESPONSES

Neonatal Hypertrophy

Palpable breast tissue, sometimes with a considerable degree of engorgement, is evident in nearly all full-term infants of both sexes during the first week or so of life. It is the result of the passive hormonal stimulation to which the fetus is exposed during the last few weeks in the uterus. It has been suggested that the less frequent occurrence of neonatal breast hypertrophy in premature infants is due to the immaturity of the fetal breasts, which are therefore less responsive to hormonal stimulation.

The swelling is seldom great enough to cause concern. Rarely, however, engorgement is quite marked and, in a small percentage of cases, may be accompanied by a discharge of clear or cloudy fluid from the nipples ("witch's milk"). The enlargement and discharge subside and disappear spontaneously after a few days unless an attempt is made to express the fluid; in the latter instance, persistence of the swelling may be prolonged and the breast may become inflamed. The presence of neonatal hypertrophy beyond the immediate neonatal period is a matter for concern; a few cases of carcinoma of the breast have been reported in infants (Blanc y Fortacin, 1917).

Asymmetry

Since each breast arises from an independent anlage, it is not surprising that one

breast bud will appear before its counterpart responds to the hormonal stimulus that induces breast growth at the onset of puberty. One breast frequently forges ahead in its growth and may be considerably larger than the other during puberty and early adolescence (Fig. 23-5). However, as a general rule, with the passage of time the lagging breast will eventually catch up, so that when breast development and body growth are complete, both breasts will be within reasonably normal size limits. The breasts of any normal adult, however, are rarely found to be truly equal in size and are seldom symmetrical if they are accurately measured.

In some instances, asymmetry is so marked that an adolescent girl is seriously embarrassed by her appearance. The distress may prevent her from participating in sports and in the social life of her peer group. She should be assured that something can be done about the matter when she has completed her growth. That knowledge alone will be a comfort to her until corrective surgical procedures can be taken. During the period when she is waiting for the breasts to assume their ultimate size, she may use a cosmetic prosthesis on the smaller side. Hormonal therapy is not effective. Cosmetic surgery, whether augmentation or reduction, is postponed until breast and body growth are complete. It can be assumed that breast growth has ceased when measurements of the breasts of a girl over 17 years of age remain unchanged for a period of six months. Table 23-4 shows the

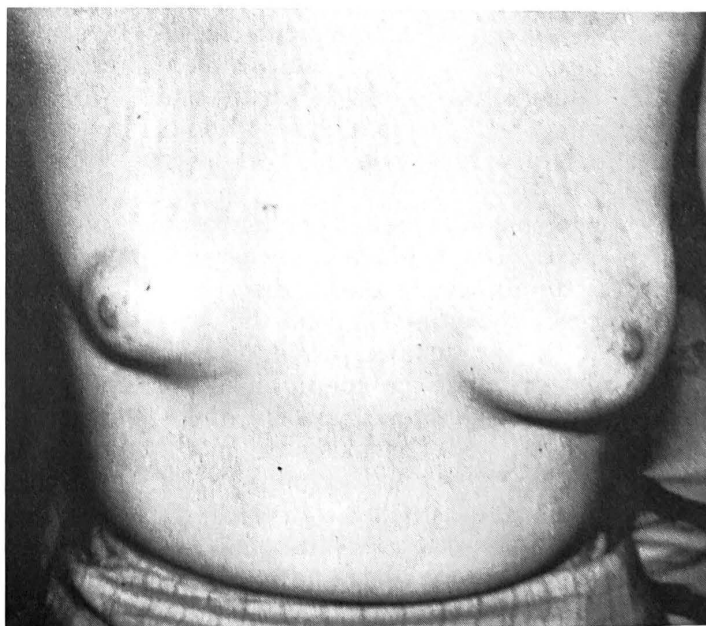


Figure 23-5. Breast asymmetry in an adolescent girl.

Table 23-4. BREAST MEASUREMENTS IN A PATIENT WITH BREAST ASYMMETRY

Age	Right Breast		Left Breast	
	Measurements	"Breast Units"	Measurements	"Breast Units"
12 years	17 × 15 cm.	255	14 × 10 cm.	140
13 years	18 × 15 cm.	270	14 × 10 cm.	140
14 years	20 × 18.5 cm.	370	16 × 12.5 cm.	200
14 1/2 years	23 × 20 cm.	460	17 × 13 cm.	221
15 years	23.5 × 20 cm.	470	17.5 × 13 cm.	327.5
16 years	24 × 20 cm.	480	17.5 × 13.5 cm.	236.25
17 years	27 × 20 cm.	540	20 × 15 cm.	300

The "breast units" show an increase in size in both breasts with each repeated examination. However, note that the right breast was always considerably larger than the left breast during the five years this patient was followed up with this original technique for measuring breast growth. (From Capraro, V., and Dewhurst, C.: Breast disorders in childhood and adolescence. *Clin. Obstet. Gynecol.*, 18:25, 1975.)

difference, measured in breast units, of an adolescent with breast asymmetry.

Painful Enlargement

Most girls have little or no discomfort in their breasts during puberty. Occasionally, however, a child will be brought to the physician because she complains of pain in the region of one or both nipples. Examination will reveal a tender, discrete, discoid nodule, the breast bud, under one or both nipples. Such discomfort, although most often transient, may persist for a considerable time; the nodule is gradually converted into the enlarging gland.

Quite a few pubescent girls complain of breast tenderness and swelling that occurs in a cyclic fashion during the several months prior to the menarche. Their breasts become firm, tense, and at times exquisitely tender. Palpation reveals a fine granularity in the parenchyma of the glands. The cyclic nature of the pain becomes premenstrual after the menarche. In both the pubertal girl and the postmenarchial adolescent, the cyclic pain and swelling are a response to the rising tide of estrogen, which is responsible for breast growth.

The postmenarchial patient and her family may have been frightened by a prior diagnosis of fibrocystic breast disease or chronic cystic mastitis. They can be reassured that the premenstrual pain and swelling are neither, that the condition is not neoplastic, and that it will usually disappear when hormone balances are established and the breasts have attained their full adult growth. Surgery and estrogen-progestin oral contraceptives are contraindicated. Analgesics may be required for the discomfort. The patient with heavy, painful

breasts will find that a well-fitted brassiere of the "uplift" type, worn during the daytime, and a soft, supporting one, worn while sleeping, will give her considerable comfort. Methyl testosterone, 10 mg. orally, once daily for seven days premenstrually or beginning with the onset of pain is effective in treating premenstrual mastalgia, but it ought not to be given to patients who suffer from acne or who have oily skin or any trace of hirsutism, because even such small doses as those mentioned here can produce virilizing side-effects in susceptible individuals. Danazol (17 α -ethynyl-17 β -hydroxy-4-androsteno[2,3-d]isoxazole), an antigonadotropin with minimal androgenic properties, has been used for the treatment of premenstrual mastalgia but has not been approved by the U.S. Food and Drug Administration for that purpose. Decreasing their salt intake during the last half of the menstrual cycle helps many patients. Premenstrual diuretics are also helpful, but we prefer not to prescribe them for adolescents whose problem is essentially a minor disturbance of a physiologic process.

Micromastia

Failure of breast growth, despite the presence of mammary gland tissue, ranges from complete absence of any palpable breast development to well-formed breasts that the patient thinks are too small. An adolescent who is 15 or 16 years of age and who has no sign of breast growth also usually has primary amenorrhea and failure of development of her other secondary sexual characteristics. Such problems will be considered later with the other causes for non-development of the breasts during adolescence.

There are some young women who men-

struate regularly and whose other secondary sexual characteristics are well developed, yet whose breasts, although evidencing some growth, are so small that they create major psychologic problems. Rarely, the hypoplasia is very marked, and it is only when the patient is pregnant that there is any fullness beneath her nipples.

Some girls with micromastia give a history of a similar problem in other female members of their families. Occasionally when breast development is defective, the supporting structures are also inadequate and there is a considerable degree of ptosis, often giving the breasts a sagging or flattened contour.

There is no definitive explanation for micromastia. It has been suggested that it is due to a defect in the formation of the primitive breast tissue during embryonic development. An alternative to this suggestion is the hypothesis that the breast does not respond to normal levels of circulating estrogen. If the latter is correct, micromastia is the result of a defect in end-organ response.

Whatever the cause, adolescents whose breasts are abnormally small may have serious emotional disturbances because of their affliction. For the individual girl, for her peers, and in fact for Western society in general, the female breast is a symbol of feminine sexuality. Failure to have full, well-developed breasts may make it difficult for the adolescent to establish her feminine self-image and to enter into the heterosexual relationships that should occur during adolescence. Patients who are seriously disturbed may be so affected emotionally that they forgo athletics, swimming, sunbathing, and the social life of their age group.

Merely reassuring the unhappy, flat-chested girl that small breasts are not pathologic is not adequate treatment. She needs reassurance that something can eventually be done for her. There is no really effective nonsurgical treatment during adolescence. Exercising the arm, shoulder, and thoracic muscles may raise the breast somewhat, but it will not increase breast size. Estrogen or estrogen-progestin contraceptive pills rarely increase breast size to any marked degree. Pregnancy makes small breasts larger, but the glands recede to their former size after the cessation of lactation. The adolescent is counseled and told that she can be helped by a surgical augmentation

operation but that such a procedure must be postponed until her breast and body growth are completed. During her waiting period prior to surgery she may wish to use a padded brassiere. It can be assumed that breast growth has ceased when breast measurements remain unchanged for a period of six months and the patient is over 17 years of age.

Macromastia (Virginal Hypertrophy)

Massive breast enlargement is called virginal hypertrophy when it occurs, as it often does, during puberty and early adolescence. The rapid and excessive increase in size, usually of both breasts (Fig. 23-6), is a disorder of unknown etiology. It has been suggested by Hollingsworth and Archer (1973) that it is an abnormal end-organ response to normal serum estrogen levels. Abnormally high levels of estrogen have not been reported in adolescent patients with massive breast hypertrophy.

Macromastia causes both psychologic trauma and physical discomfort. The heavy masses, which are a constant drag on the patient's shoulders, produce fatigue, backache, and poor posture. If the breasts are extremely large, the patient may have recurrent premenstrual mastalgia owing to congestion and fibrocystic disease. Intertrigo beneath large, pendulous breasts is often a troublesome problem. Kaye (1973) described a thoracic outlet compression syndrome associated with massive breast

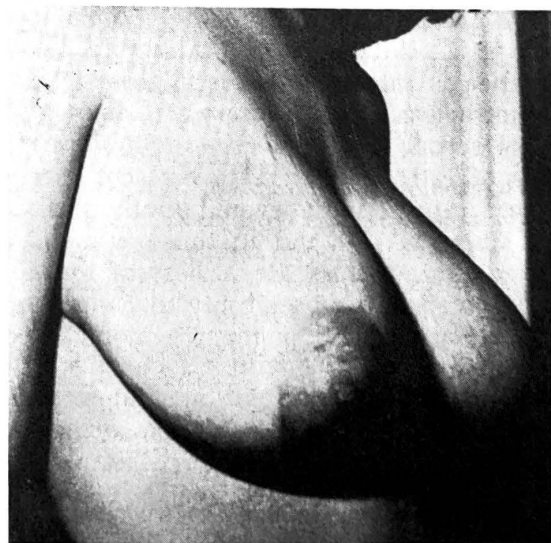


Figure 23-6. Moderate breast hypertrophy in a 15-year-old girl.

hypertrophy. The syndrome is characterized by lower cervical pain, numbness in the arms and hands, and signs of pressure on the ulnar nerve.

The mental distress of patients with very large, heavy breasts, like that of patients with micromastia, can be very great. Often its severity is not recognized by the adolescent's family or physician. Even moderate hypertrophy may affect a girl's social life. Younger patients may avoid athletics and games because of the ridicule to which their large, bouncing breasts subject them.

The only accepted definitive treatment for virginal macromastia is a reduction mammoplasty or subcutaneous mastectomy. However, Goldfarb (1975) suggested to one of us (V.J.C.) that Danazol might be of value in treating the condition. Recently it has been given to a 13-year-old girl with massive breast hypertrophy. Her breasts regressed remarkably while she was receiving the hormone. Several courses were given, because there was a moderate exacerbation of breast nodularity and growth after each course was completed. Danazol is not accepted by the U.S. Food and Drug Administration for the treatment of macromastia, and further investigation is necessary to establish its efficacy for this condition.

Galactorrhea

Galactorrhea that persists for a considerable length of time may be physiologic during or after a normal pregnancy. In gynecologic practice, however, the condition is usually found in patients who have not recently been pregnant and who also have secondary amenorrhea of hypothalamic-pituitary origin. Although galactorrhea is rare in adolescent girls, it may nevertheless be encountered in those who have secondary amenorrhea following the use of estrogen-progestin oral contraceptives, in those with severe hypothyroidism (see Fig. 14-17), and in those who have taken tranquilizers. Regardless of the apparent cause, the possibility that a patient has a pituitary tumor must be considered when she presents with galactorrhea not associated with a recent pregnancy. The diagnosis and treatment of galactorrhea is discussed in detail in Chapter 17, Amenorrhea and Hirsutism.

Atrophy

Obese girls who go on a crash diet and who lose a considerable amount of weight

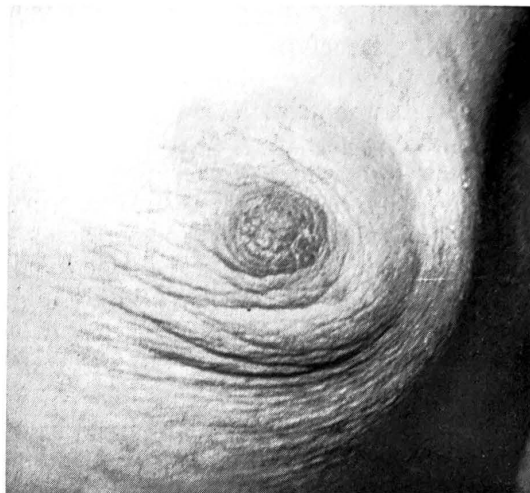

Figure 23-7. Atrophy and sagging of the breast with senile-appearing skin in a 16-year-old girl who had rapidly lost 65 pounds on a crash diet.

in a relatively short time frequently show marked loss of fat in their breasts. The rapidity of fat loss does not allow time for the skin over it to shrink properly. As a result, wrinkling occurs, giving the skin a senile appearance (Fig. 23-7). Patients with anorexia nervosa and other disorders that cause rapid loss of weight are also likely to display similar signs.

NONDEVELOPMENT

Adolescents who display failure of breast development can be placed in one of four groups: those who are merely late starters, those who have normal mammary gland tissue but are lacking the endogenous estrogen needed to stimulate breast growth, those who have no breast tissue, and those whose breast tissue is unable to respond to estrogen.

Breast growth begins for most girls sometime between their eighth and thirteenth birthdays; as a general rule it precedes the menarche by a year or two (Tanner, 1962). There is considerable variability, however, in the time between the beginning of breast growth and the menarche. The great majority of adolescents will have quite well-formed, although perhaps not fully developed, breasts by the time they are 15 years old.

Since there is a range of five years for the normal commencement of breast growth, it is not surprising that a group of girls of the same chronologic age will show a considerable difference in the time their breasts begin to develop. On the other hand, girls

of the same somatic (bone) age will tend to experience the beginning of breast development at about the same time.

Late-starting girls whose sexual development lags behind that of their classmates are demonstrating the wide variation in the chronologic age at which sexual maturation commences. It should not be assumed that late starters are abnormal. Often a history will be obtained of a similar growth pattern in a patient's mother or female siblings. However, failure of any evidence of breast development to appear by the time a girl is 14 years of age is a matter for concern and investigation.

The breasts of girls with disorders causing the failure or suppression of ovarian function do not develop even though the girls possess normal mammary gland tissue (Fig. 23-8). Untreated or poorly controlled virilizing congenital adrenal cortical hyperplasia, the premenarchial adrenogenital syndrome, gonadal dysgenesis, and pituitary hypogonadism are among some of the conditions causing hypoestrogenism and, secondarily, failure of breast development. Patients with a 46XY karyotype, excepting those with the androgen insensitivity (testicular feminizing) syndrome, who have been reared as females will complain of a lack of breast development (Fig. 23-9). Castration during childhood, as a result of bilateral ovariectomy or roentgen therapy, will of course be followed by nondevelopment of the breast unless estrogen is given during the period when puberty would normally occur.

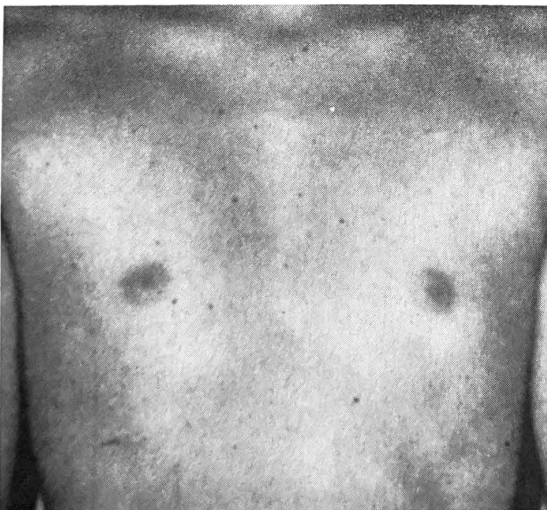

Figure 23-8. Absence of breast development in a 15-year-old patient with a 45XO karyotype and gonadal dysgenesis.

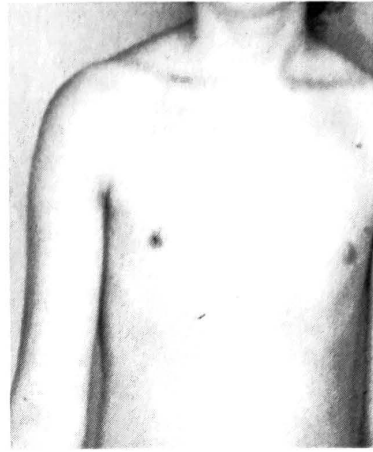


Figure 23-9. Absence of breast growth in a 16-year-old 46XY patient reared as a girl.

Most young patients who complain of nondevelopment of their breasts are seen during their mid-teen years. They also have primary amenorrhea, underdeveloped genitalia, and estrogen-deficient vaginal cytoscsmears. The other secondary sexual characteristics are poorly developed in patients with gonadal dysgenesis, pituitary hypogonadism, and those disorders in which the secretion of androgenic hormones, as well as estrogen, is not increased during puberty. In all of these conditions, control of the disorder that is inhibiting ovarian function or the administration of estrogen to those patients who are unable to produce their own ovarian hormones will cause the development of normal breast tissue.

Absence of the breast (amastia) is a rare congenital anomaly that is discussed hereinafter. Roentgen therapy for tumors of the thoracic wall during childhood may result in a radiation reaction in the immature mammary gland with subsequent failure of development at puberty.

A most distressing example of unnecessary nondevelopment of the breast is seen after a surgeon, unacquainted with breast development, has unwittingly excised a small lump beneath a child's nipple under the impression that it was a tumor, when actually it was a breast bud that was starting to grow somewhat ahead of its counterpart.

Estrogen, administered in relatively small amounts, will cause development of the breast in the hypoestrogenic patient. In many cases, corrective surgery of the augmentation type will help those whose breasts are either absent or unable to respond to estrogen.

PRECOCIOUS BREAST DEVELOPMENT

The breast normally does not begin to develop until a child is eight or more years of age. Breast growth before eight is precocious. It is thought that in some cases premature breast growth is the result either of increased sensitivity of the mammary gland to small amounts of estrogen or of a slightly increased secretion of estrogen. In children with isosexual precocity, premature breast development is due to an increased secretion of estrogens. Precocious breast growth, however, may also be a sign of pseudoprecocious puberty resulting from estrogen-secreting tumors, intracranial lesions, or exposure to exogenous estrogens.

Pennington (1974), without differentiating the causes of the precocious puberty, studied the hormonal levels in cases where the clinical findings varied from a slight degree of breast development or pubic hair growth to the premature onset of regular menstrual periods. He found that estrogen, 17-oxosteroid, and 17-oxogenic steroid levels were raised markedly in roughly half of the cases.

Precocious Thelarche

Precocious thelarche is the growth of one or both breasts without other signs of sexual maturation before the age at which puberty would normally occur (Wilkins, 1965). It may be present in infants less than one year of age or may not become apparent until a girl is five or six years old. There is some question as to the correctness of this definition of premature thelarche and of the belief that it is due to an increased end-organ response to normal levels of estrogen. Although the children with premature thelarche do not show other clinical signs of sexual maturation, they are nevertheless usually larger than girls of the same chronological age. They frequently have a somewhat advanced bone age, and their vaginal epithelial cells may show slight estrogen stimulation. Also, several studies in addition to that by Pennington (1974) have demonstrated that there are, in many cases, increased plasma estrogen, FSH, and LH levels (Kenny et al., 1969; Capraro et al., 1971; Jenner et al., 1972).

The parents are assured that precocious thelarche is not life endangering, is not neoplastic, and in many instances disappears in a matter of months. If it does not,

they are told that breast growth and function will not be abnormal after the menarche.

Constitutional Isosexual Precocity

Differentiation between premature thelarche and breast growth associated with constitutional isosexual precocity depends on demonstrating the absence of increased adrenal androgen production, which is always present in cases of constitutional isosexual precocity but does not occur with premature thelarche.

Breast growth is but one finding in cases of constitutional isosexual precocity (Fig. 23-10). There is also growth of pubic hair, an estrogenized vaginal mucosa, maturation of the external genitalia, enlargement of the uterus, and, frequently, cyclic menstrual periods. The patients' growth is accelerated, and they have an advanced bone age.

Pseudoprecocious Puberty

The child with pseudoprecocious puberty presents much the same picture as does the one with constitutional isosexual precocity. There may, however, be clinical

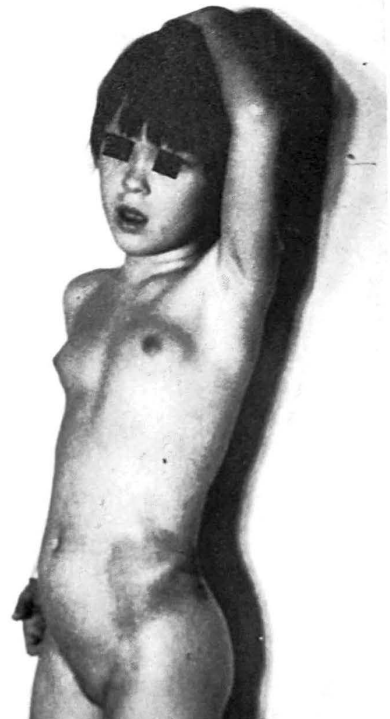

Figure 23-10. Precocious breast development in a 5-year-old child with the McCune-Albright syndrome. She had been menstruating for several months.

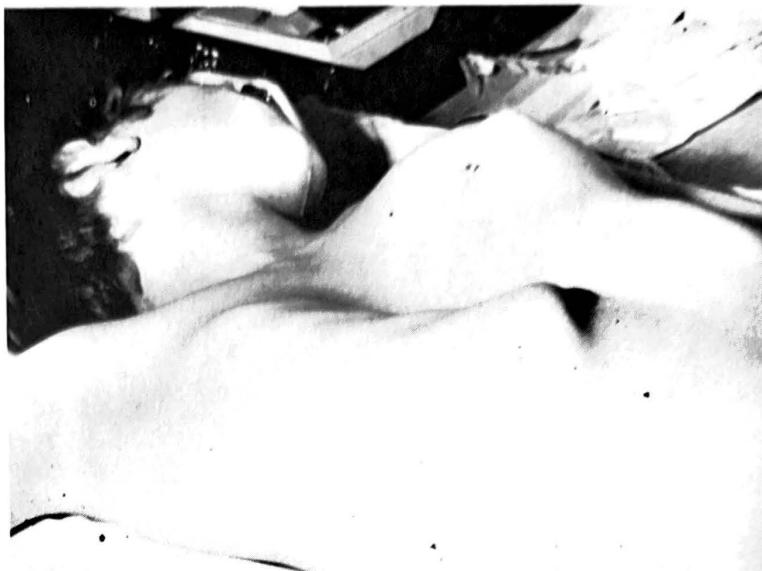

Figure 23-11. Fourteen-year-old patient with congenital absence of the right breast. There is also absence of the pectoralis muscles and a defect in development of the ribs.

evidence of an intracranial lesion or of an ovarian or adrenal tumor. A history may be obtained of prolonged exposure to exogenous estrogen. Discovery and removal of the source of estrogen is, of course, the definitive treatment for patients in this group.

The differential diagnosis, clinical features, and management of sexual precocity is described in Chapter 14.

Occasionally, an obese child may have a sufficient deposit of fat in the breast to simulate premature thelarche. An important finding in the clinical differential diagnosis between constitutional isosexual precocity, pseudoprecocious puberty, premature thelarche, and obesity is that the nipple shows maturation only in cases of constitutional isosexual precocity and pseudoprecocious puberty; in the other two conditions it remains immature. Also, the breasts of the obese child will become smaller if she loses weight.

CONGENITAL ANOMALIES

Congenital anomalies of the breast may be unilateral or bilateral. Total absence of a breast (amastia) is uncommon. It is usually associated with abnormalities of the thoracic wall, including absence of the pectoralis muscles and defects in the rib structure (Fig. 23-11). Multiple breasts (polymastia), shown in Figure 23-12, do not cause a patient trouble unless the supernumerary gland becomes engorged post partum.

Congenital absence of the nipple (athelia) is the rarest of all breast anomalies, but two

or more nipples within a normal-appearing areola are encountered rather frequently. Congenital inversion of one or both nipples is sometimes a matter of concern to an adolescent, but she can be assured that inversion rarely creates a problem for a young nonpregnant patient. Inversion, however, is believed to be a factor in causing the subareolar abscesses that are some-

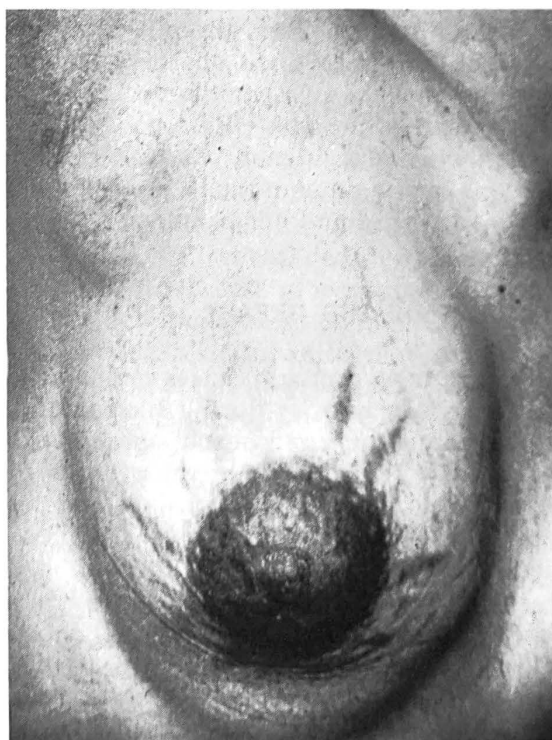

Figure 23-12. Fifteen-year-old patient on fourth postpartum day. An engorged supernumerary breast caused a painful swelling in the right axilla.

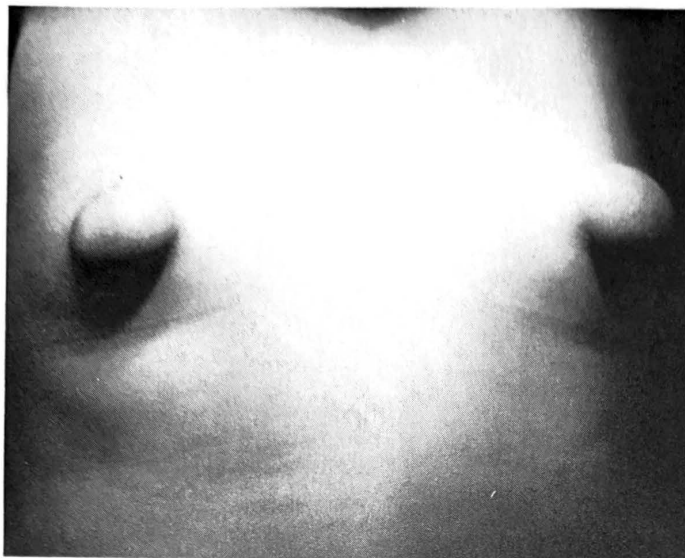


Figure 23-13. The whole areola forms a soft, rather flabby projection without there being a distinct nipple. The patient was 12 years of age. (Courtesy of Dr. Irmi Rey-Stocker.)

times seen in older women. Hypertrophy of the nipple, forming a large, bulbous, rather flabby mass atop the areola (Fig. 23-13) rather than a firm, erectile papilla, is an unusual anomaly, which is not described in most essays on the breast insofar as we can determine. It is asymptomatic in the pubertal girl; its possible effect on breast feeding is not known.

It is best if these abnormalities are discovered before the girl is aware of the role the female mammary gland plays in the sexual and social mores of today's breast-conscious society. Then the physician can offer an explanation to the parents and prepare them to give emotional support to the patient when she enters adolescence. Reassurance that, in many cases, corrective surgery can be done in the future is helpful to the older girl and her parents.

INJURIES OF THE BREAST

The three most common causes of trauma to the breast are injuries during sports, automobile accidents, and sexual assault. Depending on the type of injury, there may be ecchymoses, swelling, contusions, lacerations, or hematomas. Contusions and hematomas are treated with ice packs applied to the injured area during the first 24 hours and warm compresses thereafter. Human bites are highly infectious; the patient who has suffered one should receive antibiotics systemically, and the wound should be either drained or not sutured.

Burns of the chest may occur in young children as a result of contact with hot

liquids, hot metal, or burning garments. The burned area is cooled immediately after the injury. Antibiotics are administered systemically. Treatment of the burned area includes biological dressings and topical antibiotics. A severe burn may destroy not only the nipple but also the underlying immature gland tissue.

INFECTIONS OF THE BREAST

Breast infections may occur during the neonatal period. Rudoy and Nelson (1975) reported 39 cases of breast abscesses in infants whose ages ranged from one to seven weeks. Infections of the breast are rare in adolescents except for those patients who develop acute mastitis and abscesses post partum. Treatment consists of systemic antibiotics and the local application of heat. If the inflammatory process does not resolve and there is a localized area of fluctuation, the abscess is incised and drained.

Chronic areolar abscess with the formation of one or more periareolar sinus tracts is the result of obstructed drainage and inflammation in one of the lacteal ducts. The duct ruptures into the subareolar tissues, and an abscess forms. The abscess burrows beneath the areola and creates a sinus tract, which points at the areolar margin. Congenital inversion of the nipple was present in 9 of the 10 cases of chronic subareolar abscesses described by Hadfield (1960) and in 76 per cent of the cases reported by Urban and Egell (1978). Incision and drainage of a subareolar abscess is not adequate treatment because it is apt to be

followed by recurrence. Proper management is en bloc excision of the sinus, the abscess, and the major duct system.

DISCHARGE FROM THE NIPPLE

Except for the secretion from the engorged breasts of some newborn babies and the colostrum produced during pregnancy, discharges from the breasts are not normal. It is most unusual for an adolescent girl to have a spontaneous nonlactational discharge. However, since breast cancer can develop in a patient of any age, the physician ought to ask the teen-aged girls whom he examines whether or not they have noticed any secretion from their breasts. The only evidence may be a discoloration on their brassieres or nightclothes.

Discharges from the nipples may be serous, turbid, purulent, or bloody. Although the appearance may be of some diagnostic significance, it is, nevertheless, less important than the fact that it is a sign of a pathologic lesion.

Cystic ductal hyperplasia, which may occur in young patients, sometimes causes a bloody discharge from the nipple. A small, nontender, soft, nonadherent mass also is usually palpable near the areola. A bloody or brownish discharge can often be extruded from one duct orifice by pressure on the mass. Intraductal papillomas, papillomatosis, and small, chronic, subareolar abscesses are among the other benign lesions that are sometimes associated with nipple discharge, in addition to cystic ductal hyperplasia.

A brownish discharge from an areolar gland (Fig. 23-14) may simulate a discharge from the nipple itself. The discharge usually disappears within a few days or weeks (Capraro and Gallego, 1975).

Although lesions that cause a discharge are most often benign, nevertheless a discharge from the nipple is found in a significant number of patients with mammary carcinoma. Urban and Egell (1978) noted that discharge accompanied by a mass occurred in 15 per cent of patients with benign breast disorders and in 2.5 per cent of those with carcinoma. This is similar to the report by Leis et al. (1967), who found that 3 per cent of the patients with carcinoma had a discharge from the nipple as compared with 10 per cent of those with benign lesions.

The presence of a spontaneous nonlacta-

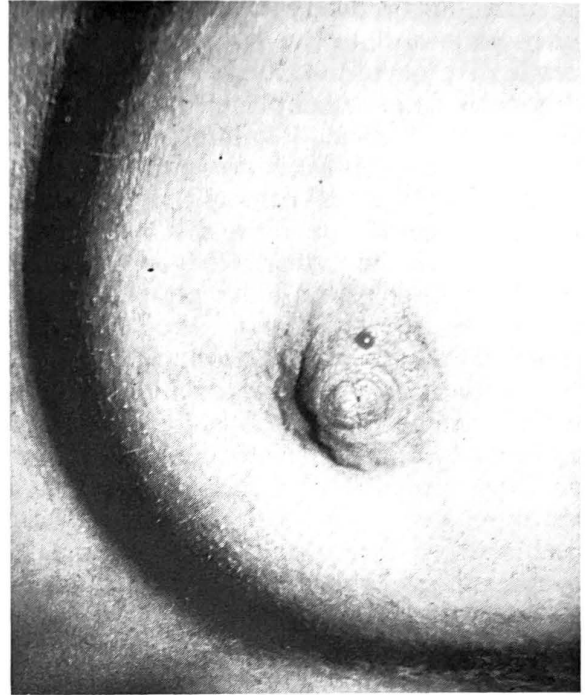


Figure 23-14. Drainage from an areolar gland of Montgomery may be confused with a nipple discharge. The patient was 15 years old.

tional discharge from the breast of a patient of any age requires investigation.

BENIGN TUMORS

Neoplasms are unusual in the breasts of premenarchial children, probably because the gland is a rudimentary organ until it is stimulated by estrogen during puberty. They are not rare in adolescent girls. Even though neoplasms develop infrequently during the first several decades of life, nevertheless the breast tumors that do occur during childhood and adolescence may be either benign or malignant, may involve any component of the mammary gland, and are of the same types that are found in adults.

The breasts of girls very near the menarche, or shortly after it, are sometimes found to have multiple, discrete, painless, firm, mobile, rounded nodules, up to 0.5 cm. in diameter, on palpation. Lesions of this character were found in approximately 3 per cent of the young adolescents coming to the Pediatric and Adolescent Gynecology Clinic at Chicago's Children's Memorial Hospital. They are not neoplastic and disappear with the hormonal adjustments that take place during the postmenarchial

period. Repeated examinations are necessary to differentiate the larger nodules from cystic dilation of the ducts, fibroadenomas, and more serious neoplasms. Surgical excision is not indicated unless a mass is believed to be neoplastic.

Any of the benign tumors that develop in the adult breast may be discovered in a child or an adolescent. Most often the child's mother or the older girl herself discovers the lump. The likelihood that the mass is malignant is very slight in such a young patient, so there need be no great rush to excise it. If the girl is postmenarchial, the lump is observed through two or three menstrual cycles. Many masses followed up in this way disappear after a few months. Those that persist, those that become larger, and those that are suspected of being neoplastic are excised.

Fibroadenomas

Fibroadenomas are the most frequently encountered breast tumors in young patients. Although they usually begin to develop at the menarche or just after it, most growths are not diagnosed until after several menstrual periods have occurred. A fi-

broadenoma may be a small nodule, not over 2 cm. in diameter, or it may be a large mass (Fig. 23-15, *A,B*) that greatly increases the size of the breast. A rapidly growing, large fibroadenoma may simulate a sarcoma. Rarely, there is an accompanying enlargement of the axillary glands. Malignant change in mammary fibroadenomas has been reported.

Fibroadenomas are examples of breast masses that persist over several months and that gradually grow larger. They are excised.

Cysts of the Breast

Solitary or multiple cysts of the breast are usually associated with fibrocystic disease. They are rare in children and are not often encountered in adolescent girls. Obstruction of a lacteal duct with the formation of a galactocele may occur in newborn infants and small children. Such masses are rounded and not tender; a few have been reported to be 5 or more centimeters in diameter. A galactocele usually does not recur after it has been aspirated. The cysts associated with fibrocystic disease contain a clear or turbid, mucoid fluid. Cytologic examina-

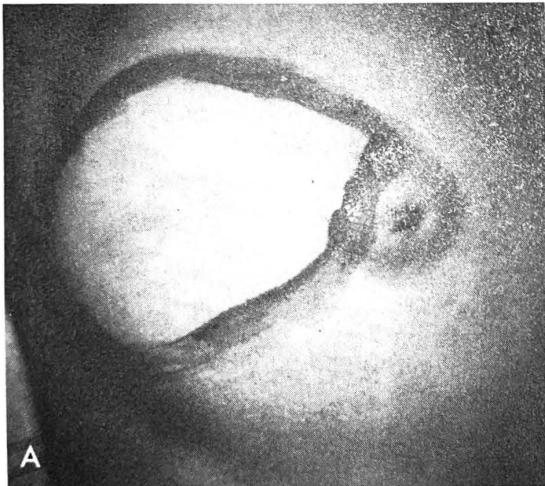
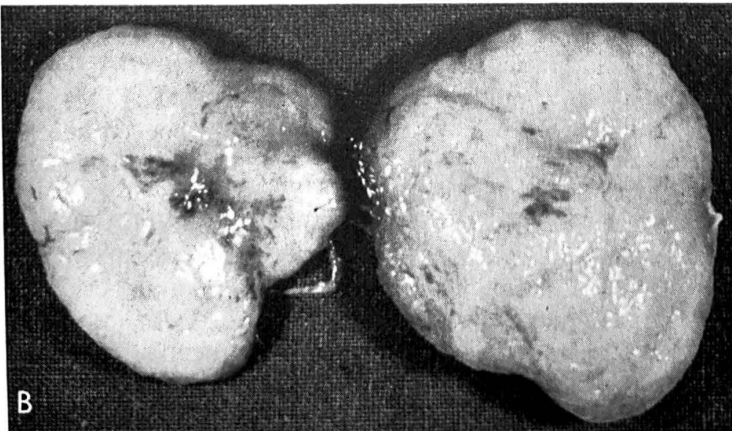

Figure 23-15. *A*, A large fibroadenoma occupying approximately one fourth of the breast of a 13-year-old girl. *B*, Gross appearance of the bisected tumor after its removal.



tion of the aspirated fluid shows occasional epithelial cells from the wall of the cyst but no neoplasia. Aspiration may be followed by disappearance of the cystic mass. Excision is indicated if the cytospin contains neoplastic cells, if the mass persists or recurs after aspiration, or if attempted aspiration fails to obtain fluid from a mass believed to be a cyst. Failure to find neoplastic cells in fluid aspirated from a cyst does not exclude the possible presence of neoplasia. It is imperative that patients who have had a breast cyst aspirated be kept under surveillance.

Cystosarcoma Phyllodes of Müller (Giant Mammary Myxoma)

This is a rare tumor of the breast that has been encountered in young patients. Stromberg and Golladay (1978) found 12 cases in the literature and added 2 of their own in girls under 16 years of age.

The pathogenesis of these growths is subject to some question. Johannes Müller (1838) gave the name "cystosarcoma phyllodes" to a type of soft or cystic large fibroadenomas that, according to Willis (1949), develop from small adenofibromas of the usual type; Willis classifies cystosarcoma phyllodes with the fibroadenomas. Stromberg and Golladay (1978) state that cystosarcoma phyllodes arise from the breast parenchyma and are neither virginal hypertrophy, fibroadenomas, carcinomas, nor sarcomas. The interested reader is referred to the paper by Stromberg and Golladay (1978) and also that by Kessinger et al. (1972), who gave specific criteria for the diagnosis of tumors of this type.

The clinical picture is one of a small breast mass that grows slowly for some time and then suddenly and rapidly increases in size. The tumors may become quite large. Examination reveals a large, sometimes huge, multilobulated, well-demarcated, mobile mass in one breast. The generally firm tumor may contain palpable cystic areas. It is not adherent to the skin or to the chest wall unless it has undergone malignant change. Rapid growth may distend the skin, causing discoloration and venous dilation. It is difficult at times to differentiate clinically between a large mass of this type, sarcoma, and unilateral virginal hypertrophy. Mammography and thermography are of little help in making the diagnosis.

Surgical exploration shows that most tumors of this type are well-circumscribed or encapsulated, cauliflower-like fleshy growths with cystic spaces, into which project polypoid masses. The spaces contain mucoid or serous fluid.

Histologically the fleshy areas show a luxuriant fibroepithelial structure, usually with an overgrowth of myxomatous connective tissue, which forms polypoid masses covered by a layer of epithelium. Willis (1949) notes that the epithelial elements within the myxomatous mass may have a sarcomatous appearance.

Most growths diagnosed histologically as cystosarcoma phyllodes are benign, but sarcomatous variants have been reported. In 3 of the 14 cases described by Stromberg and Golladay (1978), however, the tumors were malignant; one patient developed metastases and died, and in another case local recurrence of the tumor was cured by reoperation. Hertig (1980), in commenting on malignant change in giant myxomas of the breast, notes that it is the intrinsic connective tissue of the breast, i.e., the connective tissue of the lobule, that becomes sarcomatous rather than the supporting fat and fibrous tissue of the breast.

Treatment is surgical excision of the encapsulated mass. A rim of healthy tissue outside the capsule should be removed with the tumor.

Other Benign Tumors

With the exception of fibroadenomas, neoplasia of the breast is seldom encountered in pubescent girls. There are a few case reports describing lipomas and fibrolipomas in the breasts of female children. Hemangiomas and lymphangiomas of the breast may be discovered in an infant at birth or soon thereafter (Hermann, 1960).

Intraductal Papillomas

Intraductal papillomas and papillomatosis may cause nipple discharge in postmenarchial patients. Typically, the discharge is unilateral and comes from but one duct opening; a nodule is often palpable just below the areola and, on pressure, exudes a brownish or bloody discharge. Papillomas within a duct may be single or multiple. Occasionally, a whole duct system is the site of a large number of papillomas. Histologic studies have shown that there are all grades of change, from benign to obvious carcinoma, in ductal papillomas. Treatment is excision of the involved duct.

MALIGNANT TUMORS

Carcinoma of the breast occurs during childhood somewhat more often than is indicated by the infrequent case reports in the literature. Hermann (1960) quotes two investigators who found that of 12,283 patients who were operated upon for breast cancer, 0.08 per cent were under 20 years of age. In a study of 70,257 deaths of female patients from carcinoma of the breast, Pirquet (1930) discovered 7 of the patients to be under 19 years of age.

There were 33 cases of mammary carcinoma in young patients in the collective review by Hermann (1960). Eighteen of the 33 were females. Fourteen of the females were under 16 years of age; of these, 6 were less than 12 years old and one was less than 10. In a series of 7 cases of carcinoma of the breast in children reported by McDivitt and Stewart (1966), the survival rate was 100 per cent. These authors felt that the prognosis is more favorable for children with breast cancer than it is for adults. This was not the case in Hermann's collected series, however. In the latter, of the 18 females between 4 and 17 years of age, there were 4 patients who died of cancer, 8 who survived, and 6 whose course after treatment was not known. Hermann's review begins with a case reported by Heitzman in 1888 and extends over a period of 70 years. It may well be that many of the cases in the older literature were not diagnosed as early or treated as effectively as those described by McDivitt and Stewart. Certainly, early diagnosis and prompt, aggressive surgery, supplemented by such ancillary therapy as is deemed necessary, is as essential in cases of carcinoma of the breast in children as it is in adults.

Breast Biopsy

The axiom that a disfiguring scar should be avoided if at all possible when a breast biopsy is performed is particularly true when the patient is an adolescent girl who, like her peers, is keenly aware of her developing female characteristics. A circumareolar incision at the areolar margin, which follows the lines of the skin, is ideal because it leaves an almost invisible scar. Subsequent breast function is rarely, if ever, disturbed even though the incision cuts through the lacteal ducts. A radial incision, while it does not bisect the ducts,

is less desirable because it is apt to be disfiguring. Sharp dissection is preferred for excising the biopsied area or a tumor. Care is taken to insure good hemostasis. Fine sutures are used throughout the procedure. A subcuticular suture approximates the skin.

References

- Bauer, R., et al.: Management of breast lesions in children and adolescents. *J. Pediatr. Surg.*, 11:3, 1976.
- Blanc y Fortacin, D.: Neoplasias mamarias malignas en la infancia. *Rev. med. y cir. pract.*, 117:216, 1917. (Quoted by Hermann.)
- Capraro, V., and Dewhurst, C.: Breast disorders in childhood and adolescence. *Clin. Obstet. Gynecol.*, 18:25, 1975.
- Capraro, V., and Gallego, M.: Breast disorders in adolescence. *Pediatr. Ann.*, 4:82, 1975.
- Capraro, V., et al.: Premature thelarche. *Obstet. Gynecol. Surv.*, 26:2, 1971.
- Caswell, H., and Maier, W.: Chronic recurrent periareolar abscess secondary to inversion of the nipple. *Surg. Gynecol. Obstet.*, 128:597, 1969.
- Dewhurst, C.: Variations in physical signs in pubertal girls. *J. Obstet. Gynaecol. Brit. Commonw.*, 76:9, 1969.
- Dewhurst, C.: Primary amenorrhea. *Br. J. Hosp. Med.*, 14:556, 1972.
- Dewhurst, C.: Pathologic galactorrhea. In Greenhill, J. P. (ed.): *Year Book of Obstetrics and Gynecology*. Chicago, Year Book Medical Publishers, Inc., 1973, p. 193.
- Goldfarb, A.: Personal communication to V. J. C., 1975.
- Graham, P., et al.: Chest burns in young girls. *Pa. Med.*, 79:12, 1976.
- Haagensen, C.: *Diseases of the Breast*, rev. 2nd ed. Philadelphia, W. B. Saunders, 1974.
- Hadfield, J.: Excision of the major duct system for benign disease of the breast. *Br. J. Surg.*, 47:472, 1960.
- Heitzman, C.: Colloid cancer of supernumerary mammary gland in a young girl. *Med. Rev.*, 31:21, 1888. (Cited by Hermann.)
- Hermann, J.: Tumors and other enlargements of the breast. In Ariel, I., and Pack, G. (eds.): *Cancer and Allied Diseases in Infancy and Childhood*. Boston, Little, Brown and Co., 1960.
- Hertig, A.: Personal communication, 1980.
- Hollingsworth, D., and Archer, R.: Massive virginal breast hypertrophy at puberty. *Am. J. Dis. Child.*, 125:2, 1973.
- Huffman, J.: Gynecologic examination of the premenarchal child. *Postgrad. Med.*, 25:169, 1959.
- Huffman, J.: Gynecologic endocrine disorders in childhood and adolescence. *Clin. Obstet. Gynecol.*, 16:51, 1973.
- Huffman, J.: Principles of adolescent gynecology. In Wynn, R. (ed.): *Obstetrics and Gynecology Annual*, 1975. Englewood Cliffs, N.J., Prentice-Hall, Inc., 1975, p. 287.
- Jenner, M., et al.: Hormonal changes in puberty. IV.

- Plasma estradiol, LH, and FSH in prepubertal children, pubertal females, and in precocious puberty, premature thelarche, hypogonadism, and in a child with a feminizing ovarian tumor. *J. Clin. Endocrinol. Metab.*, 34:521, 1972.
- Kaye, B.: Micromastia vs. macromastia. *Med. Asp. Hum. Sex.*, 7:96, 1973.
- Kenney, F., et al.: Radioimmunoassayable serum LH and FSH in girls with sexual precocity, premature thelarche and andrenarche. *J. Clin. Endocrinol.*, 29:1272, 1969.
- Kessinger, A., et al.: Metastatic cystosarcoma phylloides: A case report and review of the literature. *J. Surg., Oncol.*, 4:131, 1972.
- Leis, H., Jr.: Clinical diagnosis of breast cancer. *J. Reprod. Med.*, 14:213, 1975.
- Leis, H., Jr.: Diagnosis of breast cancer. *CA*, 27:209, 1977.
- Leis, H., Jr., et al.: Nipple discharge — significance and treatment. *N.Y. State J. Med.*, 67:3105, 1967.
- Leis, H., Jr., et al.: Nipple discharge. *Int. Surg.*, 58:162, 1973.
- Maeda, K., et al.: Multiple myeloma in childhood. Report of a case with breast tumors as a presenting manifestation. *Am. J. Clin. Pathol.*, 60:4, 1973.
- McDivitt, R., and Stewart, F.: Breast carcinoma in children. *J.A.M.A.*, 195:388, 1966.
- Meyers, M., and Kaplan, L.: Bleeding from the nipple in infancy due to cystic ductal hyperplasia of the breast. *Ann. Surg.*, 143:557, 1956.
- Müller, J. 1838. Willis (1949) cites from Owens, F., and Adams, W.: *Arch. Surg.*, 43:588, 1941.
- Pennington, G.: The reproductive endocrinology of childhood and adolescence. *Clin. Obstet. Gynaecol.*, 1:509, 1974.
- Pirquet, C.: *Allergie des Lebensalters die Bosartigen Geschwulste*. Leipzig, Georg Thieme Verlag, 1930.
- Preece, P., et al.: Clinical syndromes of mastalgia. *Lancet*, 2:670, 1976.
- Reynolds, E., and Wines, J.: Individual differences in physical changes associated with adolescence in girls. *Am. J. Dis Child.*, 75:329, 1948.
- Roche, A., et al.: Skeletal age prediction. *J. Pediatr.*, 78:997, 1971.
- Rudoy, R., and Nelson, J.: Breast abscesses during the neonatal period. *Am. J. Dis Child.*, 129:9, 1975.
- Salazar, H., et al.: Developmental, gestational and postgestational modifications of the human breast. *Clin. Obstet. Gynecol.*, 18:2, 1975.
- Seltzer, M., et al.: The significance of age in patients with nipple discharge. *Surg. Gynecol. Obstet.*, 131:519, 1970.
- Stromberg, B., and Golladay, E.: Cystosarcoma phylloides in the adolescent female. *J. Pediatr. Surg.*, 13:423, 1978.
- Sutow, W., et al. (eds.): *Clinical Pediatric Oncology*. St. Louis, C. V. Mosby Co., 1973.
- Tanner, J.: *Growth at Adolescence*, 2nd ed. Oxford, Blackwell Scientific Publications, Ltd., 1962.
- Urban, J., and Egell, R.: Non-lactational nipple discharge. *CA*, 28:130, 1978.
- Wilkins, L.: *The Diagnosis and Treatment of Endocrine Disorders in Childhood and Adolescence*, 2nd ed. Springfield, Ill., Charles C Thomas, 1965.
- Willis, W.: *Pathology of Tumours*. London, Butterworth & Co., 1949.

(V.J.C.)